



eXceed Tx Case Presentation

Nov. 6, 2015

Courtesy of Dr. V. Kokneava
Moscow, The Russian Federation



Case Details

Patient details: Female, age 29 years

Chief complaints: Crooked teeth, wanting to improve her smile

Diagnosis: Cl. 1 dental relations. Overjet 4-5mm, Overbite 50%. Mild upper crowding, moderate lower crowding. #11 and 21 overlap. #16 posterior cross-bite. Mild Lower midline shift.

Treatment plan: Level and align. Open bite. Expand and solve #16 cross-bite, Procline and expand lower arch. Synchronize arches.

Fixed appliances: Ormco Damon Clear + Damon Q .022

Final wires: upper SS Damon .019 X .025, lower - SS Damon 016 * 025

Estimated treatment time: 18 months

Start date: June 20, 2014

Finish date: October 17, 2015

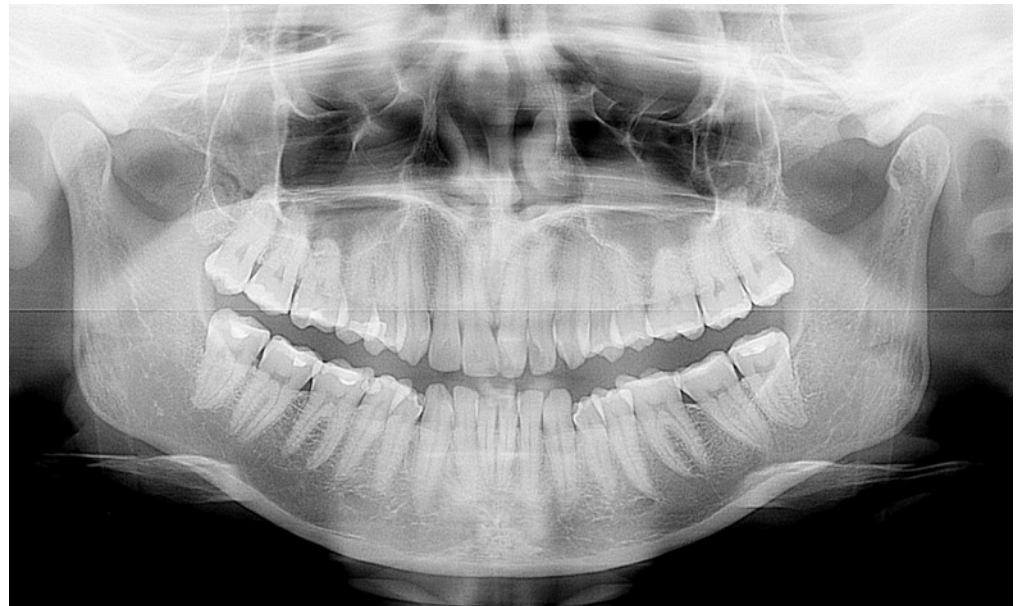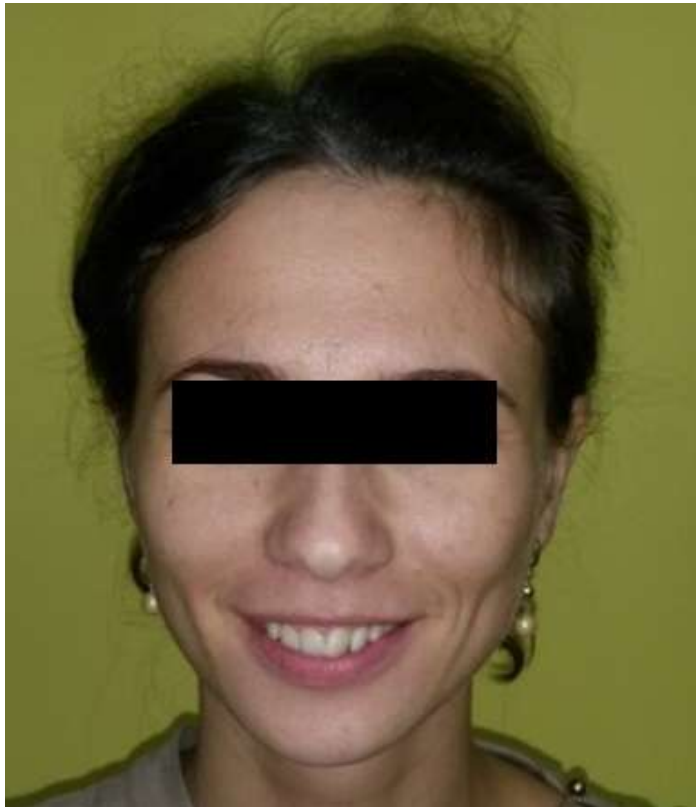Actual treatment time: 16 months.

Time savings: 2 months

Total number of visits: 11.

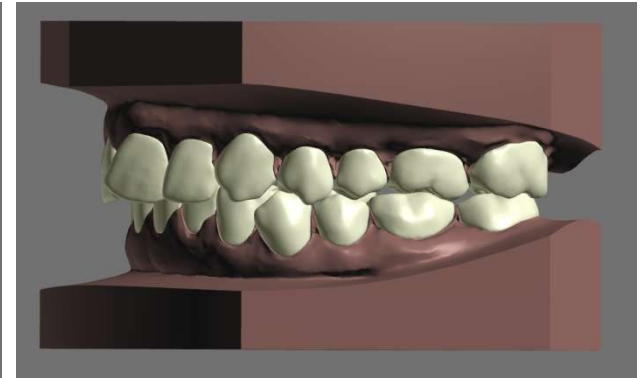
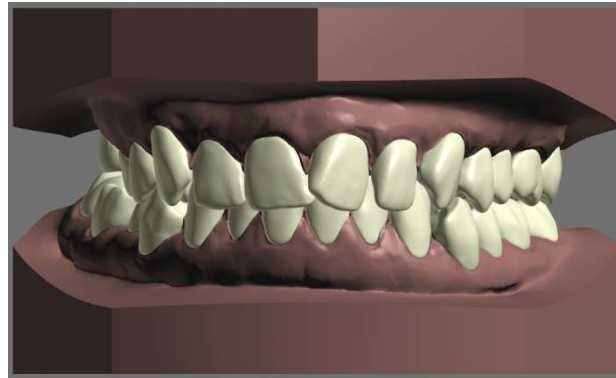
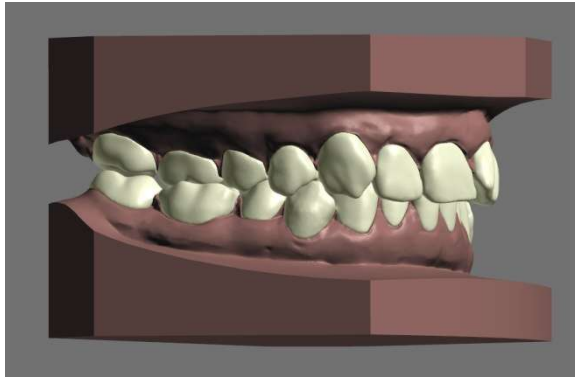
Wire changes: 5 pairs

Pre-Treatment Records-1

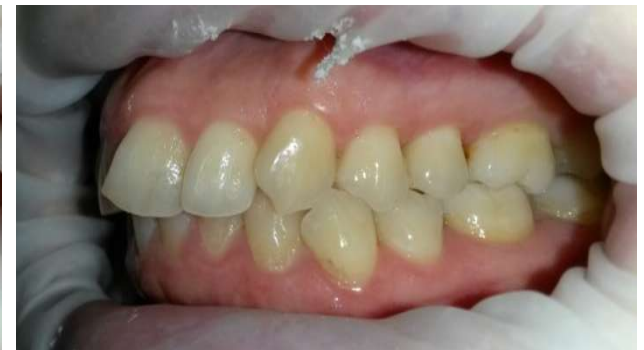
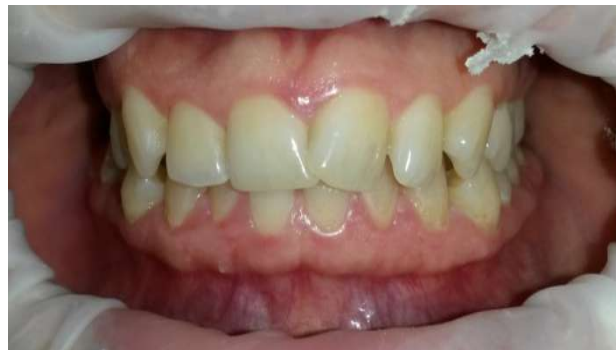
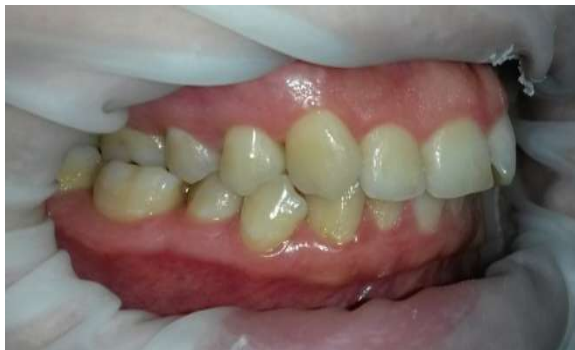Pre-Treatment Records-2

Digital Models


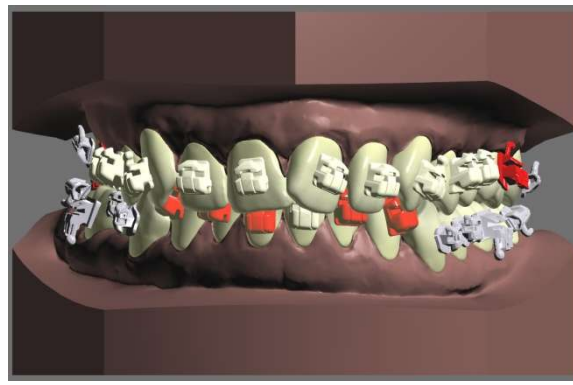
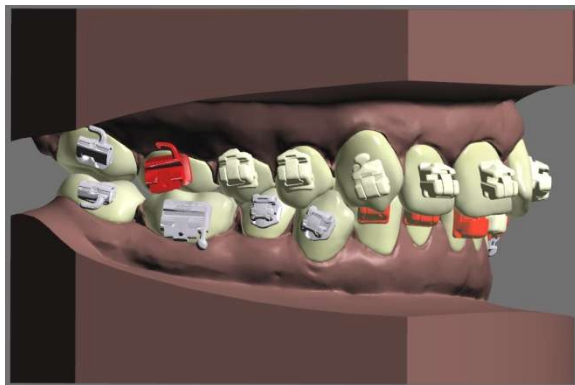


Intra-oral Images

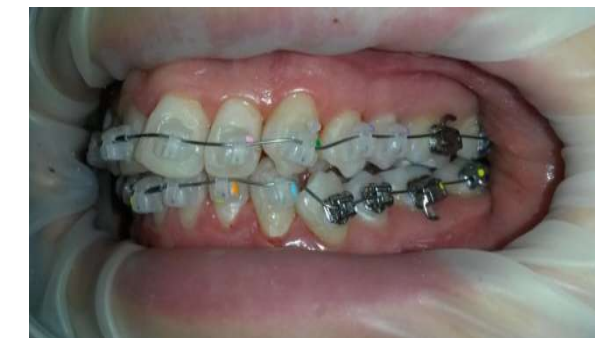
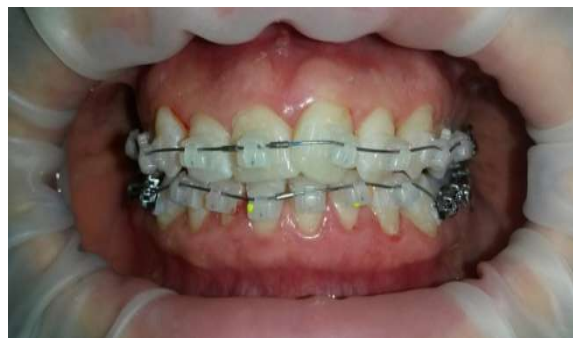
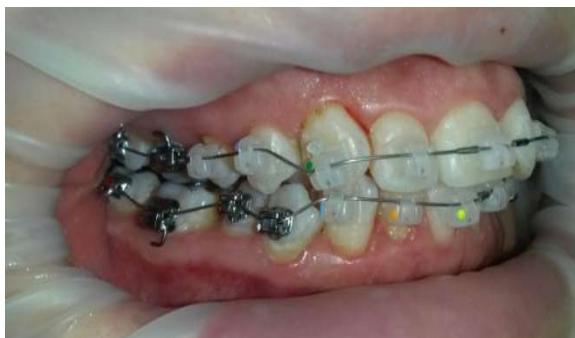Bonding

eXceed Tx Virtual Bracketing Plan (06.2014)

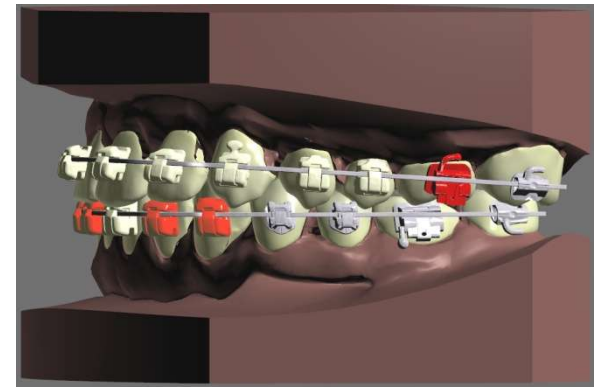
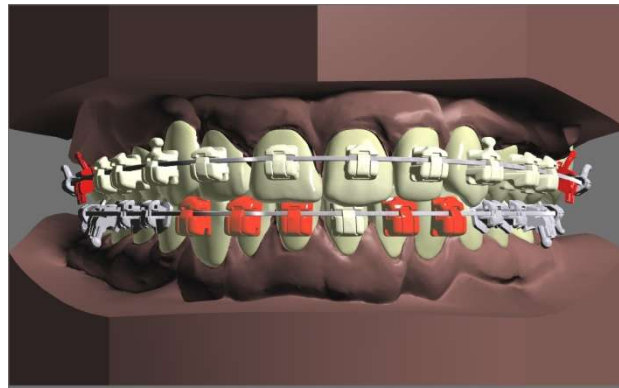
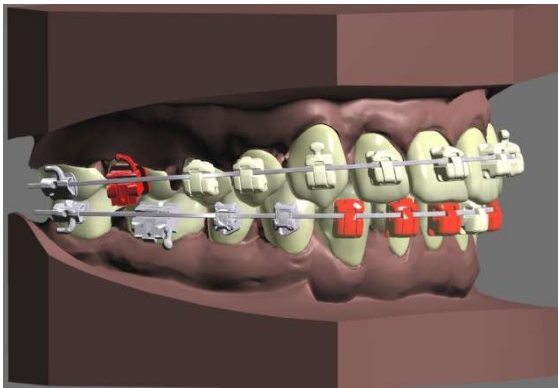


Bracket Placement with eXceed Trays (06.2014)

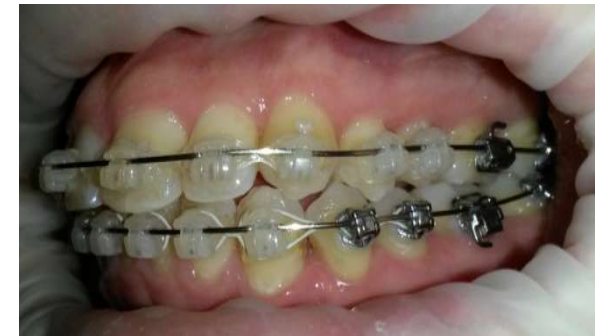
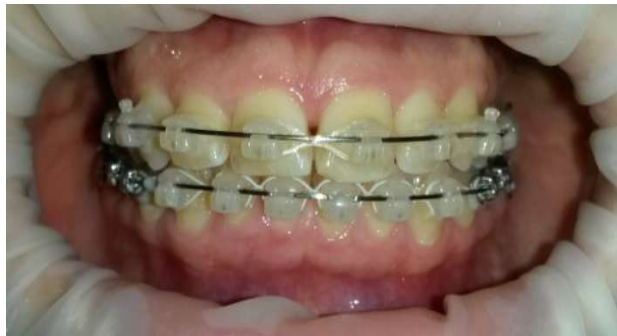
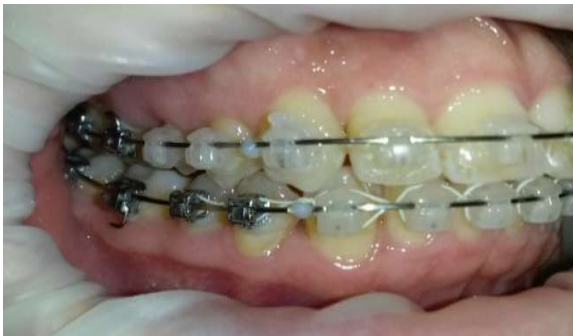Post-Treatment-1

eXceed Tx Virtual Treatment Outcome with Appliances (06.2014)

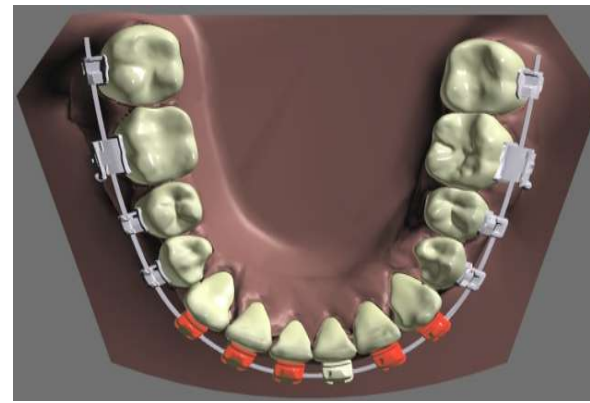
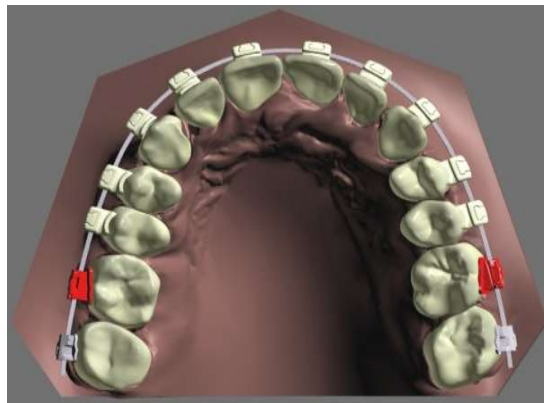


Actual Treatment Outcome with Appliances (10.2015)

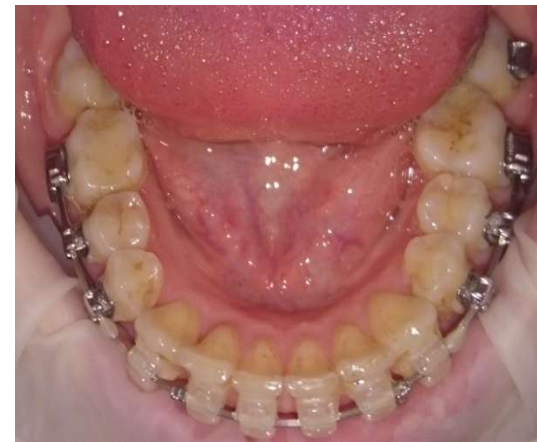
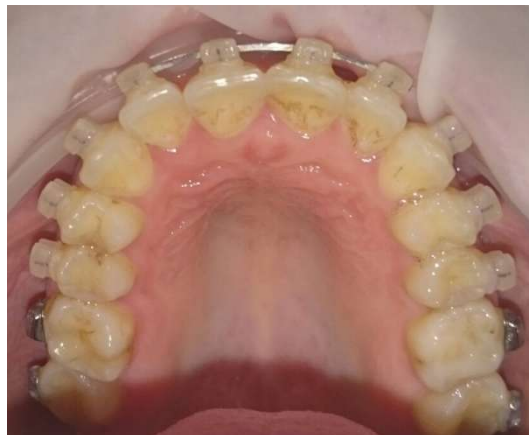
Post Treatment-2

eXceed Tx Virtual Occlusal Outcome (06.2014)

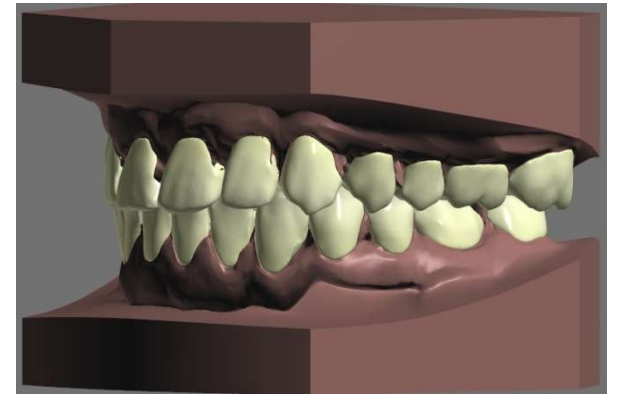
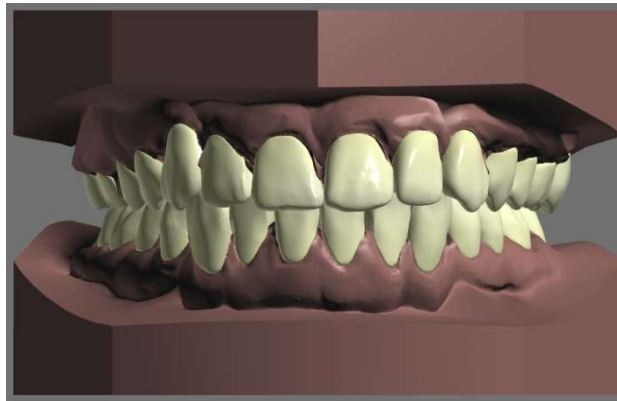
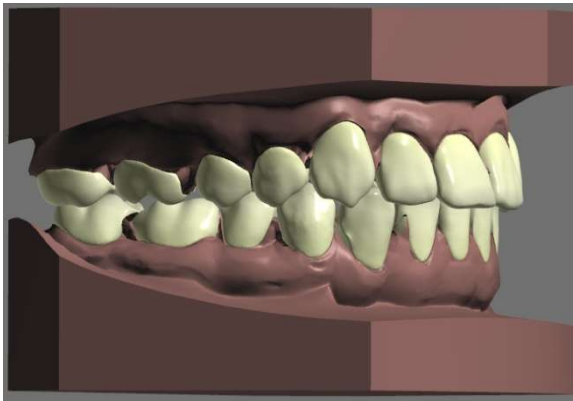


Actual Occlusal Views (10.2015)



Post Treatment-3

eXceed Tx Virtual Outcome – w/o appliances (06.2014)



Actual Outcome – w/o appliances (10.2015)

