



eXceed Tx Case Presentation

Dec. 04, 2015



Case Details

Patient details: Female, 17 years old

Chief complaints: improve teeth position and smile

Diagnosis: Mild upper and lower crowding, Anterior cross bite 22, Crooked 23, 33, 43.

Treatment plan: Level and align, synchronize arches, resolve crowding and 22 cross bite.

Fixed appliances: Ormco Damon Clear + Damon Q .022

Final wires: upper SS Damon .019 X .025, lower - SS Damon 016 * 025

Normal treatment time (without eXceed): 18 months

Start date: July 27, 2014

Finish date: July 18, 2015

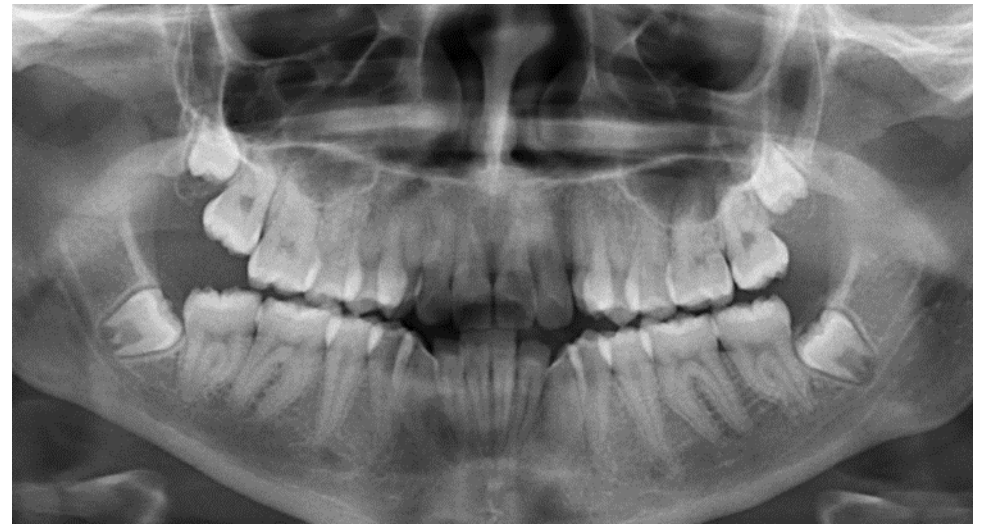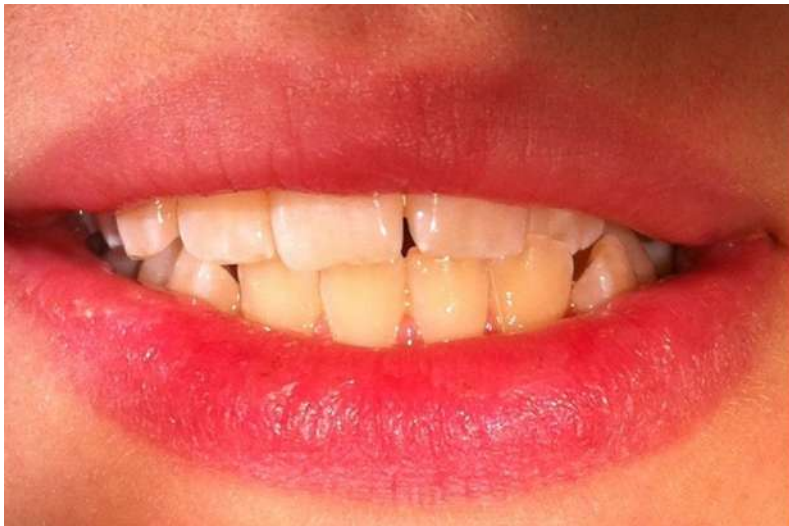Actual treatment time: 12 months.

Time savings: 6 months

Total number of visits: 8.

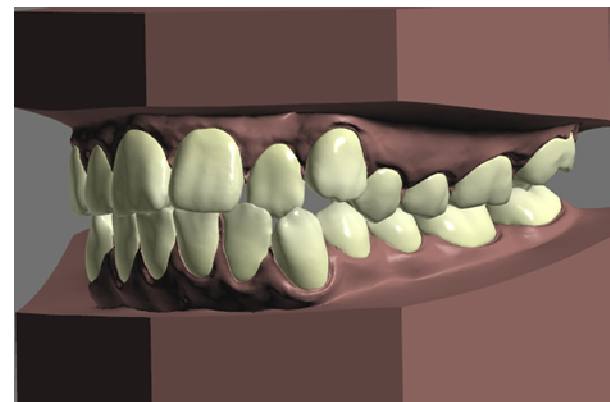
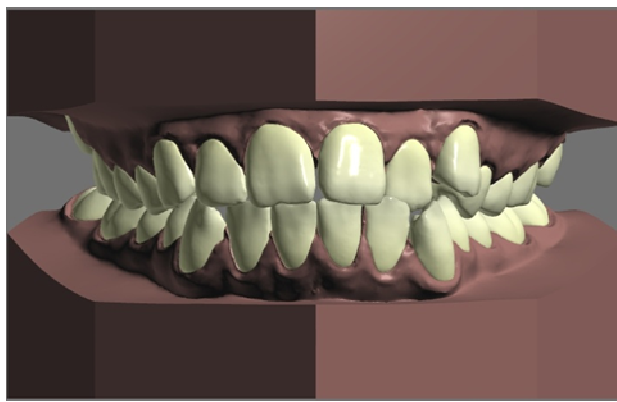
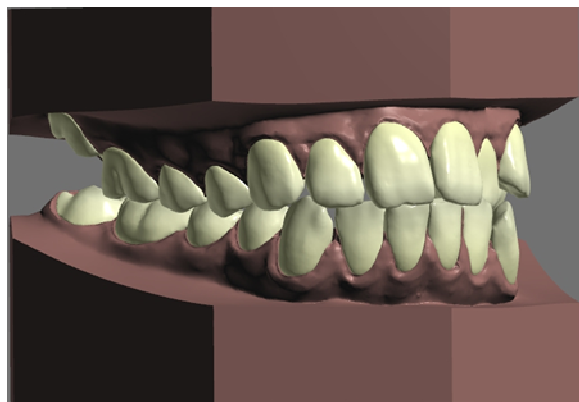Wire changes: 7 pairs

Pre-Treatment Records-1

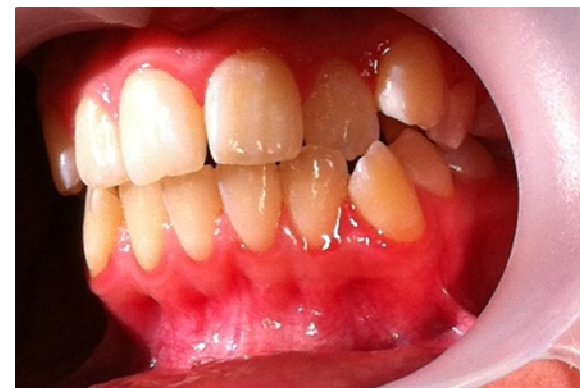
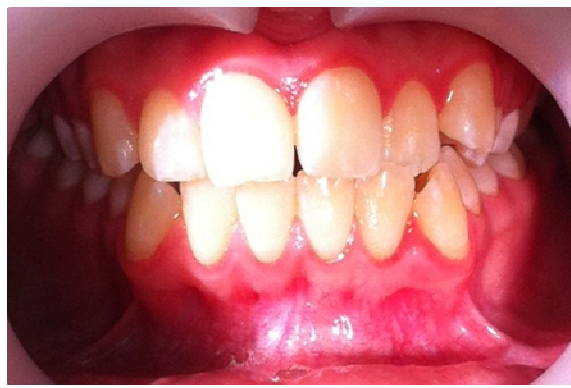
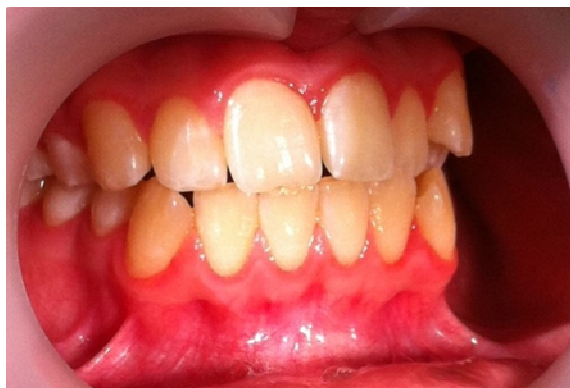Pre-Treatment Records-2

Digital Models

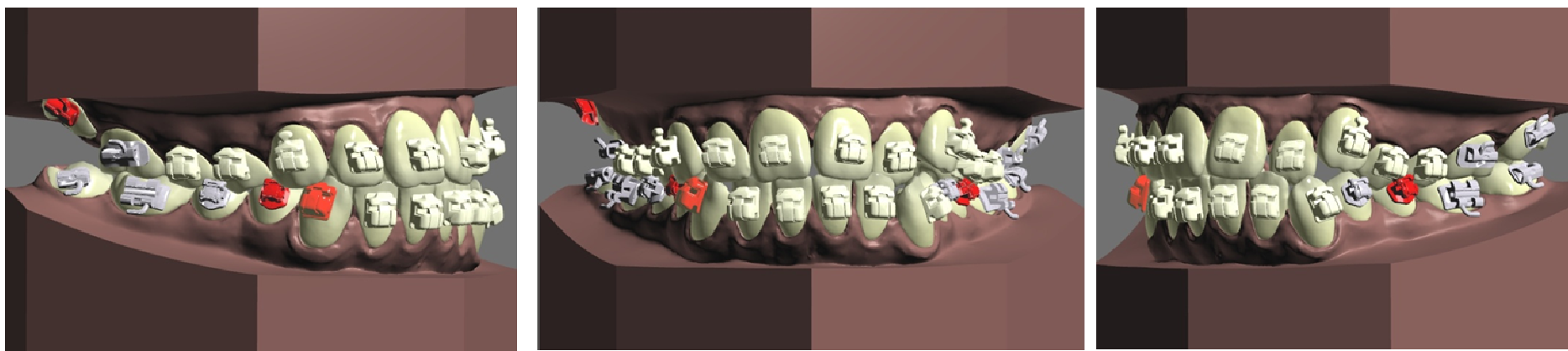

Intra-oral Images

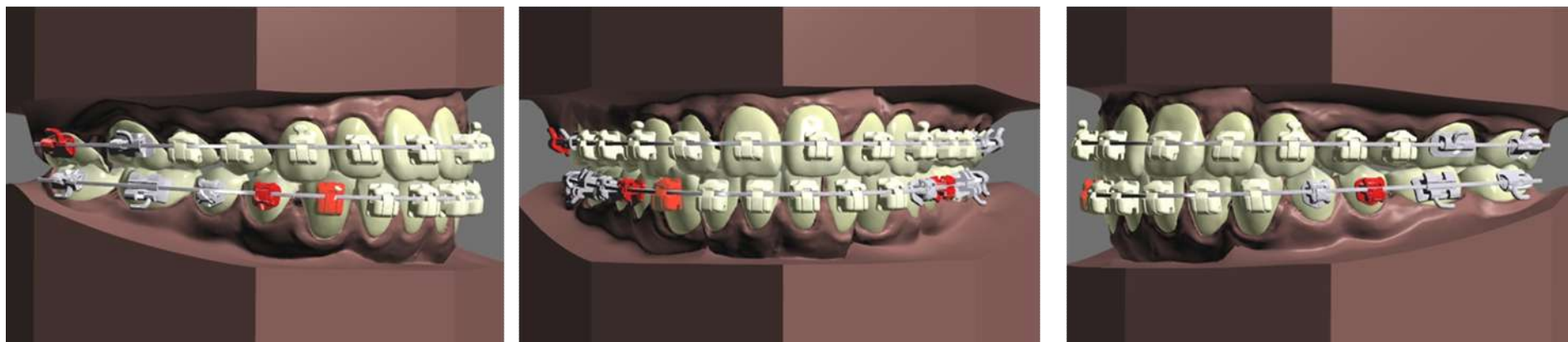


Bonding

eXceed Tx Virtual Bracketing Plan (07.2014)

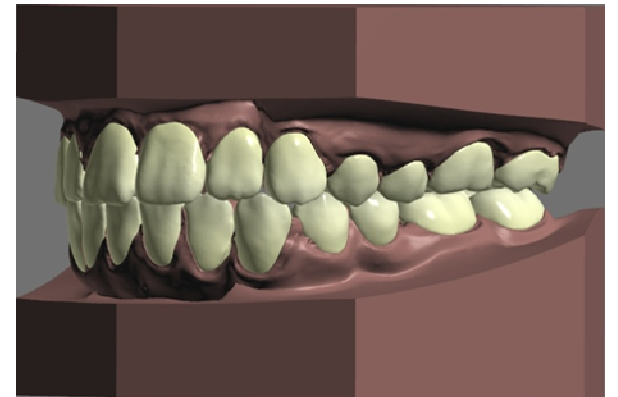
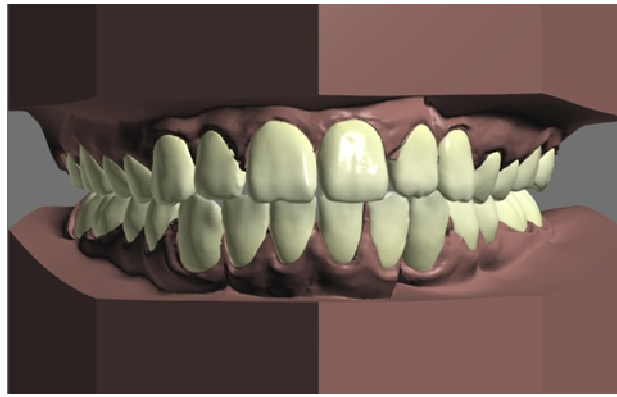
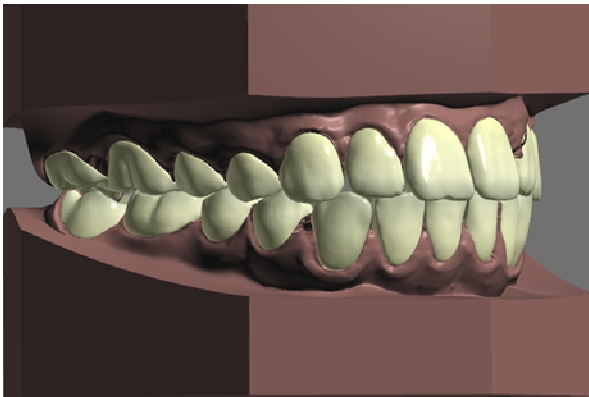


eXceed Tx Virtual Outcome (07.2014)



Post Treatment

eXceed Tx Virtual Outcome – w/o appliances (07.2014)



Actual Outcome – w/o appliances (07.2015)

